

## Three Years Follow-Up of Midface Lift Cases Done by Different Surgical Approaches

MOHAMED ABOU ZEID, M.D. and DINA MOSTAFA BADAWI, M.Sc.

*The Department of Plastic and Reconstructive Surgery, Faculty of Medicine, Cairo University*

### ABSTRACT

Facial aging reflects the effects of time, intrinsic and extrinsic factors on the skin, soft tissues, and deep structural components of the face, and is a complex synergy of skin textural changes and loss of facial volume. In this study, we are aiming at evaluating different techniques of midface rejuvenation, both surgical and non-surgical. In addition, we discuss how to choose the most suitable approach, according to each individual case, to achieve more natural and lasting results.

### INTRODUCTION

Understanding the principles on which the facial bones and soft tissues are constructed is the basis for an efficient plan for a successful long lasting midface lift with minimal morbidity [1].

Anatomically, the midface is defined superiorly by a horizontal line from the medial canthus. The inferior border is defined by a line from the inferior border of the tarsal cartilage to the lateral edge of the oral commissure [2].

The midface skeleton is bounded superiorly by the zygomatico frontal suture lines, inferiorly by the maxillary teeth, and posteriorly by the sphenoid junction and the pterygoid plates. The bones of the midface include the maxillae, the zygomatic bones, palatine bones, nasal bones, zygomatic processes of the temporal bones, lacrimal bones, ethmoid bones, and turbinates [3]. The soft tissue of the entire face is composed of five basic layers: 1<sup>st</sup> skin, 2<sup>nd</sup> subcutaneous compartment, 3<sup>rd</sup> musculoaponeurotic layer, 4<sup>th</sup> loose areolar tissue (more specifically “spaces and retaining ligaments”), and 5<sup>th</sup> the fixed periosteum and deep fascia [4].

During the process of aging, degenerative changes occur in nearly every anatomic component of the midface:

- The facial skin is subjected to two processes of aging: Intrinsic and extrinsic. Intrinsic aging is

affected by age, genetic factors, behavioural factors (e.g.: the pattern of sleep), and debilitating factors (e.g.: chronic diseases). The photodamage (extrinsic) is caused by the cumulative exposure to ultraviolet (UV) and infra-red (IR) radiations [5].

- The superficial and deep fat compartments undergo atrophy and volume loss.
- The retaining ligaments progressively attenuate at all levels, reducing the quality of fixation of the soft tissue layers.
- The midface muscle mass and strength decline by aging.
- The midfacial skeleton undergoes gradual retrusion of the infraorbital rim and the anterior maxilla. The orbit expands inferolaterally and superomedially [6].

In literature the facial aging is not attributed to a definite cause, but different theories occur. Lambros [7] showed that vertical descent of skin and subcutaneous tissue was not a major component of the midfacial aging process, and that the relative anteroposterior shifts in volume played a more dominant role. Lambros' theory is corroborated by the work of Haddock et al. [8]. Whereas Hartstein et al., stated that gravity affects the entire face and the ligaments stretch over time, leading to facial volumes descend, and the skin descends along with them [9]. Stuzin [10] described 3 themes common to all aging faces:

- First, there is descent of facial fat causing changes in facial shape.
- Second, variable amounts of deflation of facial fat are noted.
- Third, radial expansion of facial soft tissue occurs as a consequence of prolonged animation over time.

In order to develop a successful treatment plan, the surgeon must. (A) Develop a thorough understanding of the patient's goals by attentively listening to the patient's concerns. (B) Carry a careful and systematic facial analysis to determine the areas involved and the severity of the aging process in the face. (C) Perform a general systematic assessment of the patient to determine the presence of medical problems that may adversely impact the surgical result or place the patient at undue risk.

A clinical classification of the midface aging is provided by Shiffman [11] which correlates the severity of aging with the area affected.

Table (1): Clinical classification of facial aging [11].

Stage	Tear trough depth	Cheek fat loss	NLF depth
0	None	No loss	None
1	Slight to cheek fat	No loss	Slight
2	Mild into cheek fat	Slight, medially	Mild
3	Moderate	Moderate	Moderate
4	Severe	Severe, flat cheeks	Severe

## PATIENTS AND METHODS

This practical consideration of midface rejuvenation was run from January 2011 to June 2011, with 36 months post procedural follow-up.

Initially 16 patients were included, but only 10 patients continued the regular follow-up for three years, so a total of 10 patients are included, ages ranging from 40 to 66 years.

### *Inclusion criteria:*

- Good general physical and psychological conditions.
- Midfacial aging affecting all the spectrum of the midface.
- If the midface was part of a whole face rejuvenation, the patient was included, but only evaluating the midface area.
- Smoking is not exclusion by itself, but patient is strictly ordered to quit smoking at least 3 weeks before and 3 weeks after the procedure.

### *Exclusion criteria:*

- Chronic medical condition or psychological instability.
- Previous facial trauma or operation.
- Previous facial rejuvenating procedure.
- Incompliance to quit smoking in the peri-procedure period.
- Failure to continue follow-up for three years.

### Clinical decision making:

*Concerning the intervention to be done, we followed the following steps:*

- We divided the midface area into three zones:
  - The lower eye lid till the prominence of inferior orbital rim. (The tear trough).
  - The malar segment overlying the body of the zygoma. (The cheeks)
  - The nasolabial segment overlying the anterior surface of the maxilla and bordered medially by the nasolabial fold.
- Each of the three previously mentioned zones in each patient was evaluated for using the previously mentioned Shiffman classification.

Ten patients seeking midface rejuvenation were included in this study. Their mean age was 41.3 years. They underwent a combination of surgical & non-surgical procedures. This was carried either in the same session, or in 2 different sessions with a time interval in between of 2-6 weeks. The interventions done were as follows:

Table (2): Summary of the procedures done.

Intervention done	No. of cases
Extended lower blepharoplasty with orbital fat transposition (subciliary subperiosteal approach) with/without upper blepharoplasty In combination with chemical peeling of the cheeks	4
Extended lower blepharoplasty with orbital fat transposition In combination with autologous fat transfer to cheeks and nasolabial folds	3
Extended lower blepharoplasty with orbital fat transposition In combination with hyaluronic acid injection to cheeks and nasolabial folds	3

### *Evaluation of the results:*

The patients were regularly assessed for three years post operatively. By the end of this period, the longevity of the results was assessed both subjectively and objectively:

- *Subjectively:* By asking the patients whether they are still satisfied with the results or ask for renewal of the midface rejuvenation.
- *Objectively:* Done by the researchers through analyzing standardized photos, and using the previously mentioned Shiffman clinical classification of midface aging. We assessed whether the improvement in the tear trough/cheek contour/nasolabial folds depth, is still maintained or not.

**RESULTS**

This study's interest is to explore the best tools in a surgeon's hand to provide a natural and lasting midfacial rejuvenation, with the best pa-

tient's satisfaction, and the least possible complications.

The results were evaluated and depicted in the following figures.

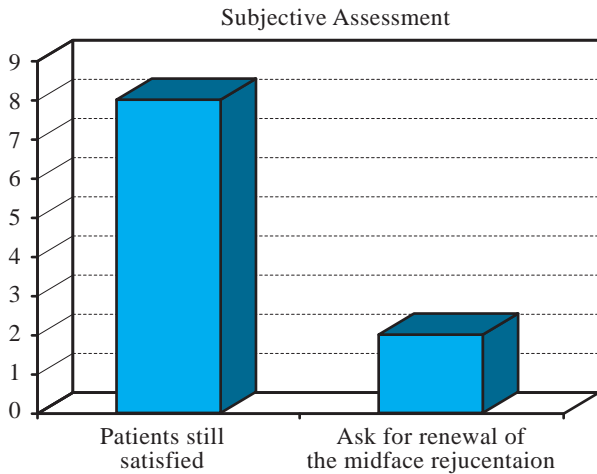


Fig. (1): Patients satisfaction scores obtained at the end of 3 years post-operative.

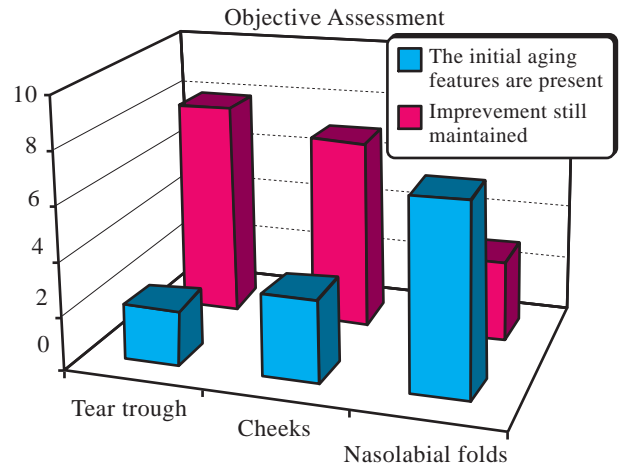


Fig. (2): Objective assessment obtained at the end of 3 years post-operative.

Cases Presentation

Fig. (3): Patient underwent lower blepharoplasty and fat injection to cheeks and nasolabial folds. Subjectively, she is satisfied. Objectively, there is maintained improvement of tear trough and cheeks contour, while the depth of the nasolabial folds shows no improvement.

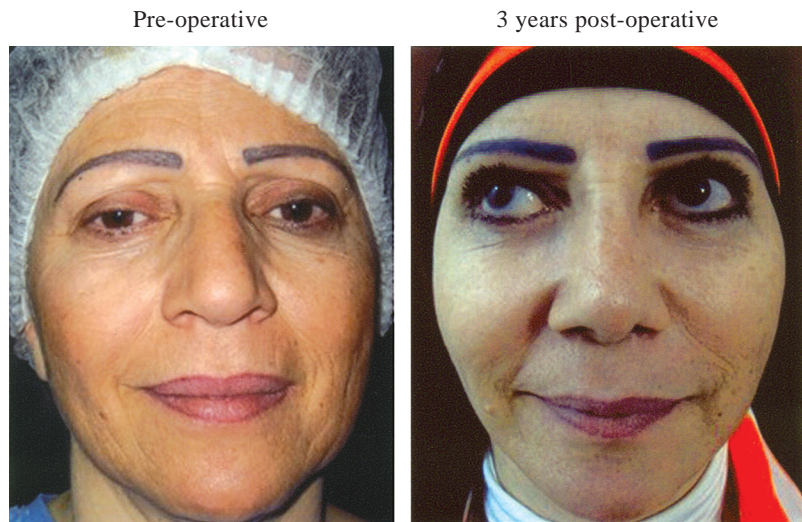
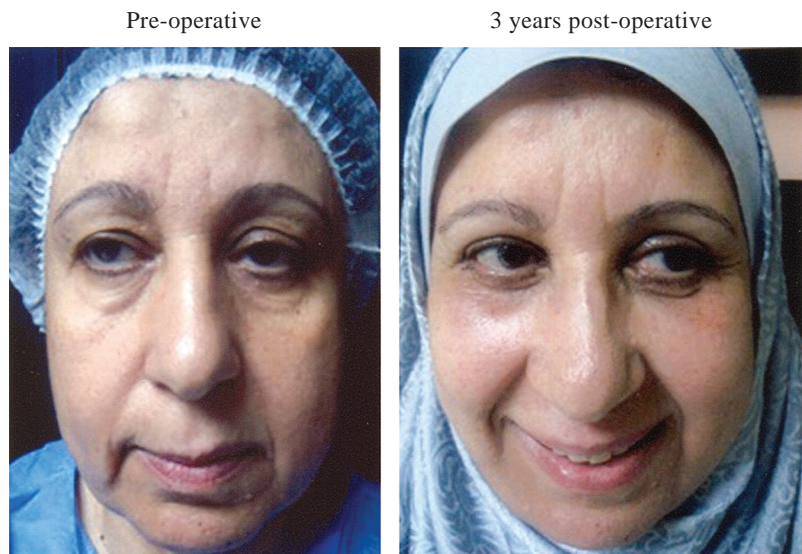
Fig. (4): Patient underwent lower and upper blepharoplasty and chemical peeling of the cheeks. Subjectively, she is satisfied. Objectively, there is maintained improvement of tear trough and cheeks contour, and the depth of the nasolabial folds.



## DISCUSSION

During our study on the face rejuvenation that lasted around three and a half years, we noticed marked progressive increase in the popularity and demand for our work especially among mid and low cultured population.

As the facial rejuvenation is an elective beautifying procedure, the question of the patient's satisfaction (the achievement of the patient's desires and expectations) is one of the major determinants of the success of the procedure. In our study, the patient's satisfaction after three years was 80%. We noticed that most cases of patient dissatisfaction were due to faults in patient assessment, as Erian advised "the surgeon must determine if the proposed patient is an acceptable candidate for the surgery desired" [11]. In a study carried to detect the anatomic predictors of unsatisfactory outcome in surgical rejuvenation of the midface, patient dissatisfaction was encountered in 14.0% of cases; the author contributed the dissatisfaction to skeletal insufficiency or loss of elasticity [11]. Accordingly, we realized that adding a non-surgical technique to improve the skin elasticity would add a synergistic effect to the patient's satisfaction. In a study done to evaluate the patient's satisfaction after surgical midface lift using Endotine device for tissue elevation and fixation, the patient satisfaction assessment averaged 97.5% [12]. However, this was at one month follow-up, which we considered quiet early to get assessment of the results efficacy and longevity, and accordingly we preferred to have our outcomes evaluated at 3 year follow-up.

In our study, the best rate of maintained improvement was for the lower eyelid/tear trough correction (80%). Mauriello [13] agreed that blepharoplasty provide more long-term effects as compared to facelift surgery. The suborbicularis occuli fat (SOOF) lift in combination with the lower blepharoplasty can give a dramatic and long-lasting effect because both the structural and the soft tissue deficits are corrected [14].

Concerning the cheek fullness and contouring, the rate of maintained improvement (as assessed objectively) was 70%. It was maintained in all cases who underwent fat injection, and in 66% with hyaluronic acid injections, and in 25% of cases with chemical peeling of the cheeks. Truswell proposed that patients who had surgical lift may benefit from the collagen stimulation effect of the injection fillers to maintain the rejuvenation effect [15].

The least objective (as well as subjective) rating was for the maintained correction of the nasolabial folds (30%). The nasolabial folds are one of the most challenging areas to correct and very difficult to maintain the correction. The efficacy of nasolabial folds correction with hyaluronic acid can be maintained for 18 months ONLY with retreatments at 4.5-9 months [16]. Although fat injection alone is a less suitable option to treat the nasolabial folds, however, when used in combination with midface lift, it shows to be "an excellent adjunct in the treatment of the nasolabial folds" [17].

### Conclusion:

Rejuvenation of the midface with a natural-looking, safe, and longlasting result is a challenge in aesthetic surgery. The ideal approach should be easy to perform, with minimal risk, significant benefit, and tailored to each patient according to individual assessment. Throughout our study, we appreciated the synergy achieved by combining multiple procedures in the midface, surgical and non-surgical in creating a more dramatic and more lasting rejuvenation.

## REFERENCES

- 1- Mendelson, Bryan and Wong, Chin-Ho: Anatomy of the aging face. (book auth.) Richard J. Warren and Peter Camillus Neligan. Plastic Surgery; Aesthetic, Volume 2. Amsterdam: Elsevier Health Sciences, pp. 78-93, 2012.
- 2- Surgical Anatomy of the Midcheek: Facial layers, spaces, and the midcheek segments. Mendelson B.C. and Jacobson S.R. 3, 208, Clin. Plast. Surg. Vol. 35, pp. 395-4, 2008.
- 3- Pendergast and Peter M.: Anatomy of Face Neck. (book auth.) Melvin a Shiffman and alberto Di Giuseppe. Cosmetic Surgery Berlin: Springer, pp. 29-45, 2013.
- 4- The Fascial Planes of the Temple and Face: An en-bloc anatomical study and a plea for consistency. De Vasconcellos, Accioli, Britto J.A. and Henin D. 7, October, British J. Plast. Surg., pp. 623-629, 2003.
- 5- Pierard, Gerard, Paquet, Philippe and Xhaufaire, Emmanuelle: Physiological Variations During Aging. (book auth.) Miranda A. Farage, Kenneth W. Miller and Howard I. Ma. Textbook of Aging Skin. Berlin: Springer, pp. 45-55, 2010.
- 6- Facelift. Warren, Richard J., Aston, Sherrell J. and Mendelson, Bryan C. 6, December, Plast. Reconstr. Surg., Vol. 128, pp. 747e-764e, 2011.
- 7- Observations on Periorbital and Midface Aging. Lambros, Val. Last. Reconstr. Surg., pp. 1367-76, 2007.
- 8- The Tear Trough and Lid/Cheek Junction: Anatomy and Implications for Surgical Correction. Haddock, Nicholas T., et al., Plast. Reconstr. Surg., pp. 31S-39S, 2009.
- 9- The Anatomic Basis of Midfacial Aging. (book auth.) Morris E. Hartstein, Allan E. Wulc and David E.E. Ho. Midfacial Rejuvenation. New York: Springer, pp. 15-29, 2011.

- 10- Restoring Facial Shape in Face Lifting: The role of skeletal support in facial analysis and midface soft-tissue repositioning. Stuzin J.M., *Plast. Reconstr. Surg.*, Vol. 119, pp. 363-376, 2007.
- 11- Siffman M.: Clinical assessment of facial aging. In P. Prendergast & M. Shiffman, *Aesthetic Medicine* (pp. 19-27). Berlin: Springer, 2011.
- 12- Erian, Anthony: Role of fat transfer in facial rejuvenation. (book auth.) Anthony Erian and Melvin A. Shiffman. *Advanced Surgical Facial Rejuvenation: Art and Clinical Practice*. Berlin: Springer, pp. 233-9, 2012.
- 13- Mauriello, Joseph A.: Upper and lower blepharoplasty with combined blepharoptosis repair. *Techniques of cosmetic eyelid surgery*. Philadelphia: LWW, 2004.
- 14- Wobig, John and Dailey, Roger: *Surgery of the midface, lower face and neck. Oculofacial plastic surgery*. New York: Thieme Medical Publishers, 2004.
- 15- Truswell, William: The three lift technique of cervico facial lifting. (book auth.) William Truswell. *Surgical facial rejuvenation: A roadmap to safe and reliable outcomes*. New York: Thieme, pp. 91-113, 2008.
- 16- Persistence and improvement of nasolabial folds correction with non-animal stabilized hyaluronic acid gel. Narins, Rhoda, Dayan, Steven and Brandt, Frederic, *Dermatol. Surg.*, Vol. 34, pp. S2-S8, 2008.
- 17- Martin, Timothy: Combined facelift and facial fat grafting. (book auth.) Foad Nahai. *The art of aesthetic surgery*. S.I.: CRC Press, pp. 1621-75, 2010.